



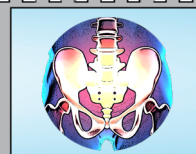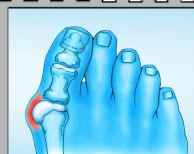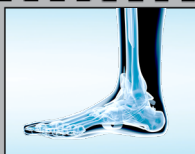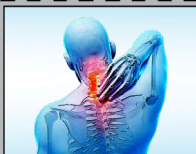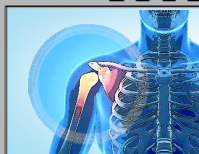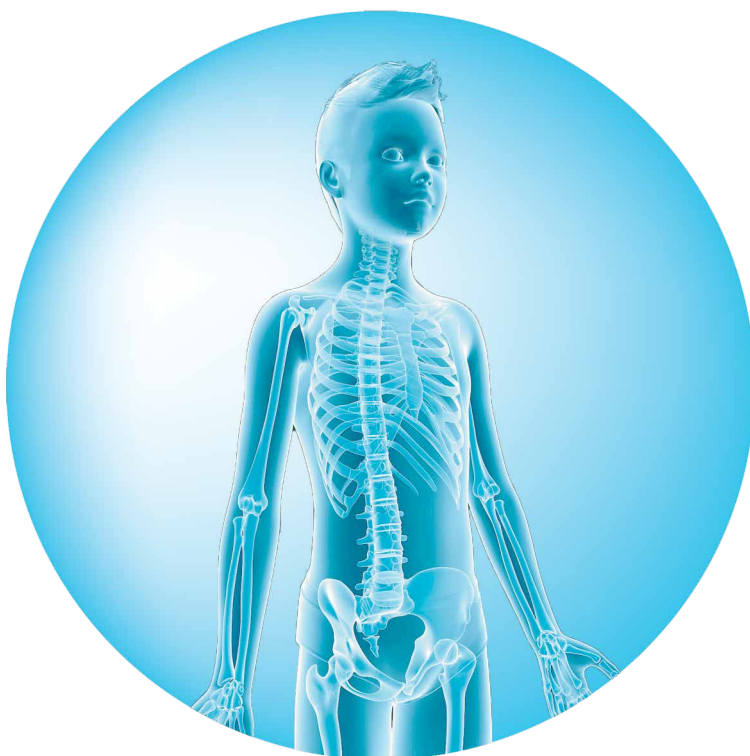asia medical specialists

亞 洲 專 科 醫 生



ISO 9001:2015
FS 550968

Scoliosis: A Common Condition Which is Frequently Misunderstood



Scoliosis, being one of the most prevalent back deformities affecting growing children, with potentially dire consequences, stirs notable anxiety among patients and their families.

There are three common types of scoliosis that affect children ¹

- Idiopathic scoliosis
- Congenital scoliosis
- Neuromuscular scoliosis

Factors that DO NOT cause Scoliosis:

- ✗ Carrying school bags
- ✗ Bad posture
- ✗ Unequal leg length
- ✗ Back injury
- ✗ Playing musical instruments
- ✗ Sports activities

Idiopathic scoliosis

Idiopathic scoliosis accounts for 80-85 % of cases. ¹ The spine is normal at birth but develops a deformity in childhood. It can occur in toddlers and young children, but the majority of cases occur from age 10 to 15 (figs. 1 and 2). Two to three percent of adolescents have scoliosis. Boys and girls are equally affected by small curves, but girls are eight times more likely to develop progressive curves. According to recent research, about one in three children whose parents have scoliosis will develop scoliosis. Scoliosis is considered a partially genetic condition. However, exactly which genes cause scoliosis is unknown. ^{2,3} It's a common believe that scoliosis cause significant back pain and functional disability. In fact, mild to moderate scoliosis typically does not cause back pain and will not cause compression onto the nerves or the heart and lung. Only very severe scoliosis curves will cause heart and lung problems. ¹

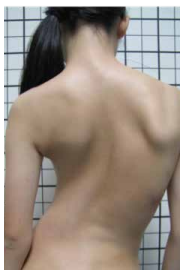

Fig. 1A Typical right thoracic scoliosis showing a curved back, tilted shoulder, prominent scapula, and trunk listing.

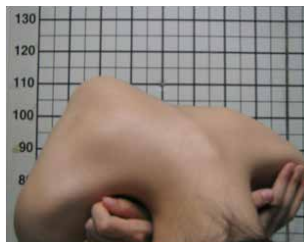

Fig. 1B Prominent rib hump during Adam's forward bending test.

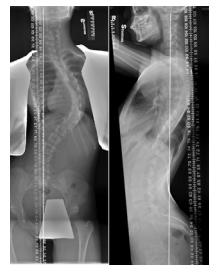


Fig. 2 AP & Lateral radiograph of the same patient.

Congenital scoliosis

Congenital scoliosis (fig. 3) starts before birth. Part of one or more vertebrae does not form completely, or the vertebrae do not separate properly. This type of scoliosis can be associated with other health issues, as well as heart and kidney problems. ¹

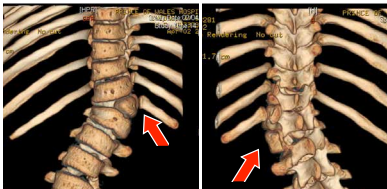


Fig. 3 3D-CT scan of patient with left T12 hemi-vertebra.

Neuromuscular scoliosis

Neuromuscular scoliosis (figs. 4 & 5) encompasses scoliosis that is secondary to nerve or muscle diseases such as cerebral palsy, spinal cord trauma, muscular dystrophy, spinal muscular atrophy, and spina bifida. This type of scoliosis generally progresses rapidly and often requires surgical treatment.

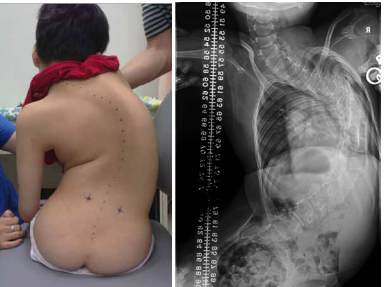

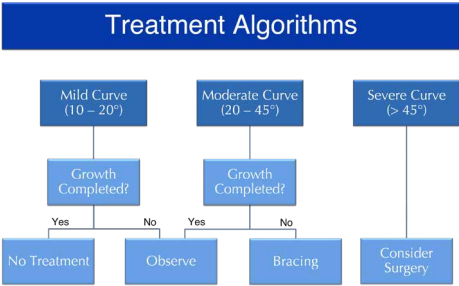
Fig. 4 (left) Severe long thoracic curve in a girl suffering from spinal muscular atrophy. Noted significant pelvic obliquity with poor sitting posture.

Fig. 5 (right) Sitting AP radiograph of the same patient. Note how the radiograph shows the true severity of the pelvic obliquity. This is best treated by surgery to allow comfortable seating.

Treatment options

There are three evidence-based options:

- Observation:** For mild curves, which are the great majority, no treatment is required if the child is skeletally mature. For growing children, a regular check-up every 4-6 months is recommended to detect curve progression.
- Brace treatment:** (figs. 6-7) For moderate curves in growing children, bracing is recommended. Braces, contrary to many patients and parents expectation, will not completely eliminate scoliosis. However, a well-fitted and diligently-worn corrective brace can significantly slow or prevent curve progression. ^{4,5}
- Surgery:** (figs. 8-10) For the very small number of children with severe curves, internal fixation is applied to the spine to correct the curve within the limits of safety. Surgery for scoliosis has been made very safe by major advances in surgical techniques including surgical navigation and the use of intraoperative spinal cord monitoring. ^{1,6,7,8}



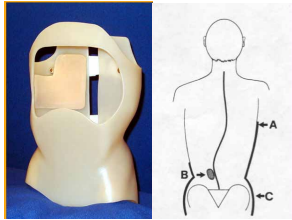


Fig. 6 Under-arm brace can be worn at day time or night time. Pressure is applied through points A, B and C.

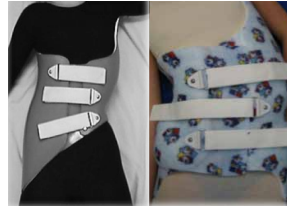

Fig. 7 Providence (left) and Charleston (right) Braces applied with the trunk bent towards the convex side for better correction of curves, are designed for bed time usage.

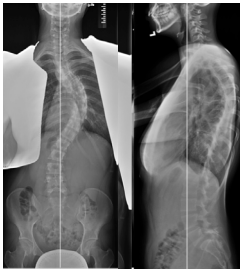

Fig. 8 AP and Lateral radiograph showing right thoracic curve before surgery.

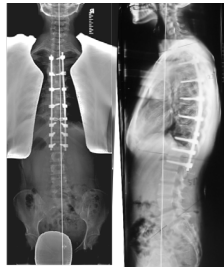


Fig. 9 Posterior spinal fusion with thoracic pedicle screws. Note spontaneous correction of compensatory lumbar curve. Lumbar spine motion is preserved.

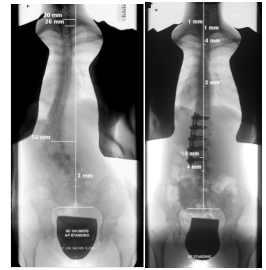


Fig. 10 Anterior Spinal Fusion for correction of left thoraco-lumbar curve.

Other treatments?

Unfortunately there is no rigorous scientific evidence that the natural history of scoliosis can be altered by any treatments other than bracing or surgery. Physical therapies or exercises; Traditional Chinese Medicine; drugs, vitamins or diets; and other treatments, remain unproven.^{9,10}

References

For the references of this article, please refer to the full version on our website:

www.asiamedicalspecialists.hk.